

# Are there still indications for the Krukenberg kineplasty ?

## Report of two patients

L. DE SMET

**SUMMARY :** Krukenberg's operation was actually described by Vanghetti in 1889. Three cases, including one bilateral case, are reported. The first case was a 36-year-old patient from a developing country. At the sixth postoperative week, the patient had regained his independence and gained 1.5 kg. The second case was a child with multiple malformations, who presented, in addition to amputation of both legs, a high amputation of the left forearm and distal fold of the right forearm. Krukenberg's operation was performed at the age of 8 months. At the age of 2 years, the child was able to eat and drink independently.

**Ann Chir Main (Ann Hand Surg), 1999, 18, n° 2, 132-135.**

**KEY-WORDS :** Amputation. – Krukenberg. – Rehabilitation.

Separation of radius and ulna in the stump of a distal upper limb amputee is known as a kineplasty. The first case was described by Vanghetti in 1889, but it was made popular by Krukenberg in 1917.

This procedure transforms the stump into a pincer (a fork) with a functional but primitive grip and preserved sensation.

More sophisticated procedures, such as free toe transfers and the development of myoelectrical prostheses has made this procedure obsolete for most previous indications.

However, this procedure still has certain indications :

- all patients who require sensory feedback (blind, bilateral amputees) ;
- children with (bilateral) absent hand ;
- patients living in areas in which prostheses and their maintenance are not available.

We report 3 procedures performed in 2 patients whom we considered suitable for this unphysiological procedure.

## CASE REPORTS

### ■ Case 1

A.A. is a 36-year-old Albanese refugee who, while handling a bomb, lost both hands just proximal to the wrist and as well as sight in both eyes. Limited recovery of vision was obtained after ophthalmological surgery, but his vision remained limited.

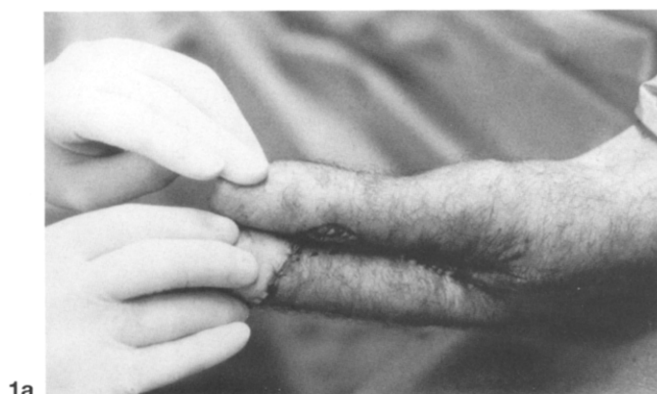A bilateral Krukenberg procedure was performed (fig. 1). Communication with this patient was very difficult, but 6 weeks postoperatively he was able to open both artificially created forks up to 34 cm and squeeze them with a 1.5 kg pinch strength (fig. 2). He then started rehabilitation of activities of daily life in order to regain independence.

### ■ Case 2

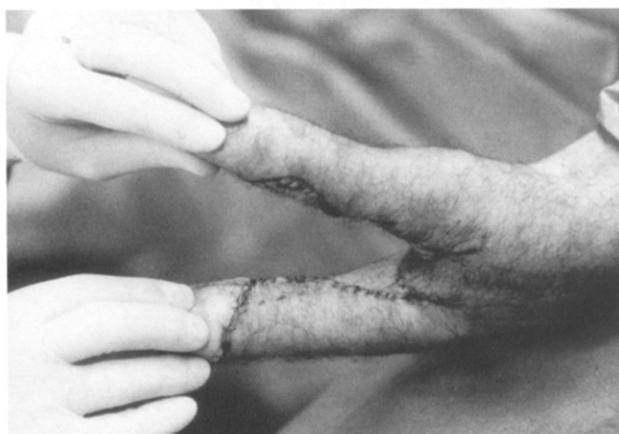R.T. was seen soon after birth with the diagnosis of aglossia-actyly syndrome. In addition to mar-

ked retromicrognasia, both forearms and both legs at the midhigh level were absent. At the age of 8 months a Krukenberg procedure was performed of the right side (fig. 3). Considerable separation of both forearm bones was possible at the end of the operation. He was recruited into an intensive rehabilitation programme with physiotherapy and occupational therapy.

At the age of 2 years he was able to manipulate small and moderately large objects (blocks), to hold a pencil and make some (primitive) drawings. With his short left below elbow stump he was able to drink and eat independently (fig. 4).



1a

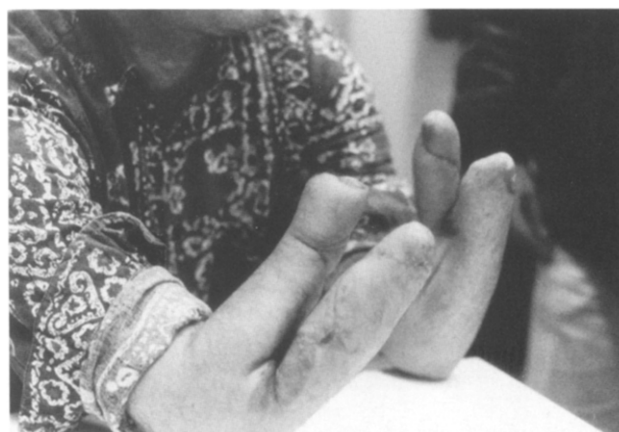

1b

**Fig. 1. – Case 1 : immediate postoperative possibilities of passive opening and closing the pincer.**

Fig. 1. – Ouverture et fermeture possible en postopératoire immédiat.

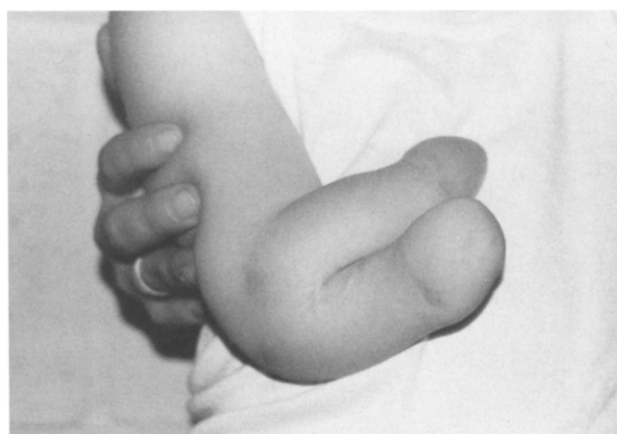
Fig. 1. – Abertura y cierre posible en post operatorio inmediato.



**Fig. 2. – Case 1 : 6 weeks postoperatively.**

Fig. 2. – 6 semaines postopératoires.

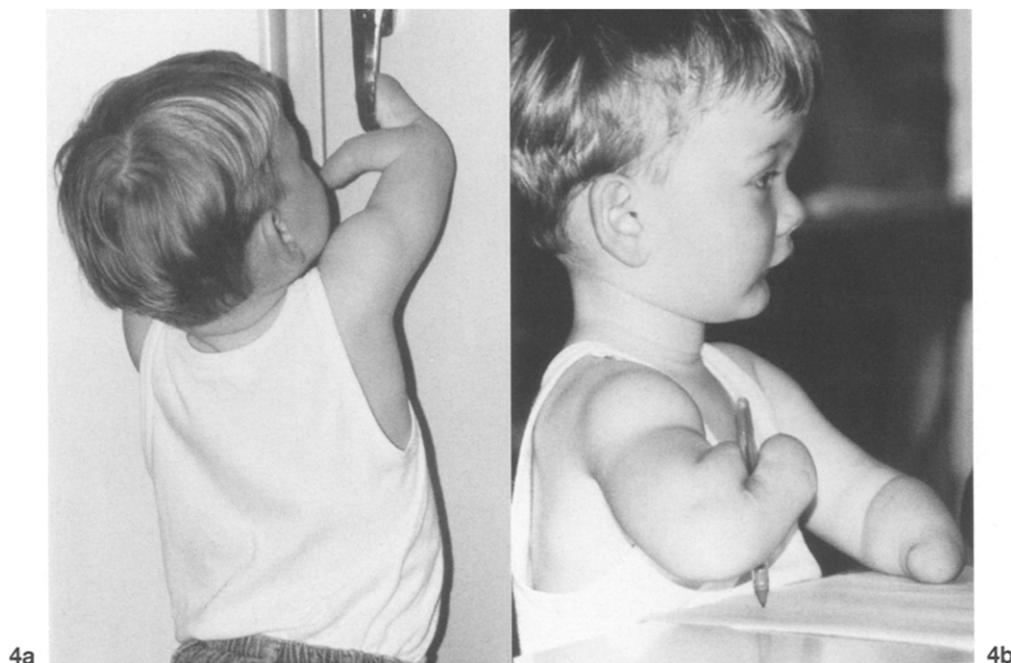
Fig. 2. – Caso 1 : Seis semanas post operatorias.



**Fig. 3. – Case 2 : clinical appearance.**

Fig. 3. – Aspect clinique.

Fig. 3. – Aspecto clínico.



**Fig. 4. – Case 2 : some applications of the «Krukenberg hand».**

Fig. 4. – Application de la main «Krukenberg».

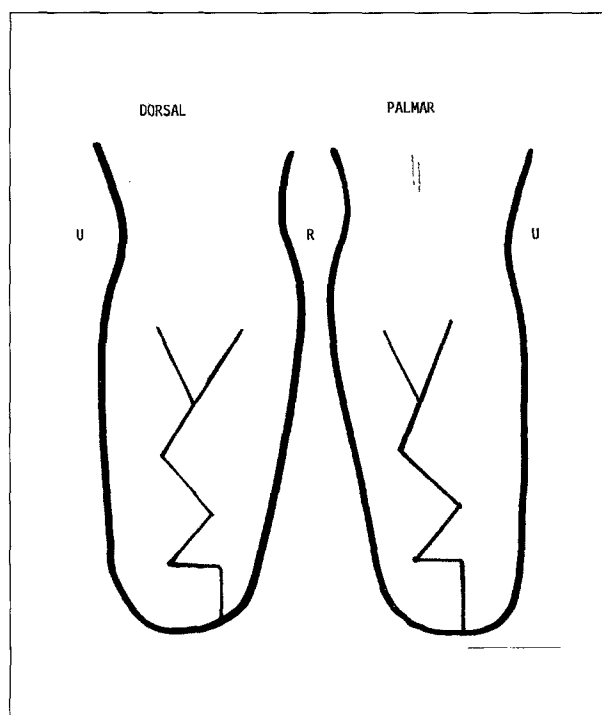
Fig. 4. – Caso 2: Aplicación de la mano «Krukenberg».

## DISCUSSION

Prehension with force and precision is an absolute requirement for an independent life. The reconstructive modalities are limited when both hands are missing. There have been reports of free toe transfers at bizarre non-anatomical sites, but the subsequent functional possibilities are not convincing.

Artificial limbs require visual feedback (which was absent in patient A.A.). In the 3 or 4 limb (juvenile) amputee (patient RT), an upper limb replacement was also an additional and major embarrassment for the patient. Artificial limbs also require facilities for good and regular technical maintenance. The Krukenberg procedure was described well before sophisticated prosthetics and certainly before the routine use of microvascular free toe transfers. There have been only a few technical modifications since then [1-12]. The skin incision is designed to preserve sensation of the extremities and to reconstruct a smooth «web» [3, 6]. Most of the experience is derived from surgeons in the Far East (i.e. China, Vietnam) [1, 2, 8, 9-11]. In Western Countries, most publications consist of case reports and limited series [4, 5, 7]. The indications can be summarized as follows :

- Bilateral adult amputee with visual impairment.



**Fig. 5. – Skin incisions on a right forearm stump.**

Fig. 5. – Incisions cutanées pour un avant-bras droit.

Fig. 5. – Incisiones cutáneas en el antebrazo derecho.

- Left sided amputee.
- Bilateral congenital amputees in order to develop the child's normal skills.
- Unilateral amputees in countries in which funds, protheses or technical facilities are insufficient or not available.

The technique has been extensively described [1-12]. We combined the skin incisions described by Marquardt and Martini [6], Martini [7] and Nathan and Truong [8] in order to preserve distal cutaneous sensation and to avoid skin grafts.

The palmaris longus muscle and the superficial flexor muscle are removed. On the dorsal side, the extensor communis is split; the extensor carpi ulnaris and extensor digiti minimi are preserved on the ulnar side and the bony and short radial wrist extensors on the radial side. On the palmar side, the brachioradialis, flexor carpi radialis and half of the flexor profundus are preserved on the radial side, the flexor carpi ulnaris and half of the flexor profundus are preserved on the ulna side. It is extre-

mely important to preserve the pronator teres and supinator muscle.

Skin closure is usually straightforward; sometimes a small skin graft is required. A bulky dressing with maximal separation of the two forearm bones is applied and physical therapy is started after 3 weeks.

A minimal length of 8 cm from the insertion of the biceps tendon is required, but 12 cm seems to be the optimal length. Excessive scarring, absent sensation and muscle contractures or extreme wasting are contraindications for kineplasty. The most important drawback however is the patient's apprehension against this disfiguring and irreversible procedure. Elbow function requires less than 70° of contracture [2].

The Krukenberg «hand» offers the patient a workable alternative. It does not preclude the use of a cosmetic or a functional prosthesis. Good psychological preparation is required before this procedure is accepted by the patient.

#### REFERENCES

1. CHAN K., MA G., CHENG J., LEUNG P. – The Krukenberg procedure. *J. Hand Surg.*, 1984, 9, 548-551.
2. GARST R. – The Krukenberg hand. *J. Bone Joint Surg.*, 1991, 73B, 385-388.
3. GU Y., ZHANG L., ZHENG Y. – Introduction of a modified Krukenberg operation. *Plast. Reconstr. Surg.*, 1996, 97, 222-226.
4. HARRISSON S., MAYOU B. – Bilateral Krukenberg operation in a young child. *Br. J. Plast. Surg.*, 1977, 30, 171-173.
5. LOOSLI-GUIGNARD R., VERDAN C. – Krukenberg's operation. Indications and limitation. *Ann. Chir. Main*, 1983, 2, 154-159.
6. MARQUARDT E., MARTINI A. – Die Krukenberg Plastik in der Modifikation von E. Marquardt. *Handchir., Microchir., Plast. Chir.*, 1985, 17, 117-121.
7. MARTINI A. – Die Krukenberg Plastik und derer zusätzliche Versorgung mit Prothesen und technischen Hilfen. *Z. Orthop.*, 1983, 121, 196-202.
8. NATHAN P., TRUNG N. – The Krukenberg operation. A modified-technique avoiding skin grafts. *J. Hand Surg.*, 1977, 2, 127-130.
9. SINAKI M., DOBYNS J., KINNUNEN J. – Krukenberg's kineplasty and rehabilitation in a blind, bilateral full-hand amputee. *Clin. Orthop.*, 1982, 169, 163-166.
10. SWANSON A. – The Krukenberg procedure in the juvenile amputee. *J. Bone Joint Surg.*, 1964, 46A, 1540-1549.
11. SWANSON A., DE GROOT-SWANSON G. – The Krukenberg procedure in the juvenile amputee. *Clin. Orthop.*, 1980, 148, 55-61.
12. TUBIANA R. – Krukenberg's operation. *Orthop. Clin. N. Am.*, 1981, 12, 819-826.

DE SMET L. – Y a-t-il encore des indications de l'opération de Krukenberg? (*En Anglais*).

*Ann Chir Main (Ann Hand Surg)*, 1999, 18, n° 2, 132-135.

**RÉSUMÉ:** L'opération dite de Krukenberg a été en réalité décrite par Vanghetti en 1989. Trois cas sont rapportés, dont un cas bilatéral. Il s'agissait d'un patient de 36 ans, originaire d'un pays en voie de développement. A six semaines postopératoires, le patient a retrouvé son indépendance avec une prise d'un kilo et demi. Le second cas concerne un enfant polymalformé qui présentait, outre une amputation des deux jambes, une amputation haute de l'avant-bras gauche et du pli distal de l'avant-bras droit. A l'âge de 8 mois est effectuée l'opération de Krukenberg. A 2 ans, l'enfant boit, mange de façon indépendante.

**MOTS-CLÉS:** Amputation. – Réhabilitation. – Krukenberg.

DE SMET L. – ¿ Hay indicaciones de la operación de Krukenberg?

*Ann Chir Main (Ann Hand Surg)*, 1999, 18, n° 2, 132-135.

**RESÚMEN:** La operación de Krukenberg realmente fue descrita por Vanghetti en 1989. Se presentan 3 casos de los cuales uno bilateral. Se trataba de un paciente de 36 años, originario de un país en vía de desarrollo. A la sexta semana post operatoria le paciente recuperó su independencia con una prensión de un kilo y medio. El segundo caso se trataba de un niño polimalformado que presentaba, además de una amputación de las dos piernas, una amputación proximal del antebrazo izquierdo y del pliegue distal del antebrazo derecho. A 8 meses de edad se efectuó la operación de Krukenberg. A 2 años, el niño bebe y come de manera independiente.

**PALABRAS-CLAVE:** Amputación. – Krukenberg. – Rehabilitación.